

## MALARIA INFECTION IN ANOLIS LIZARDS ON MARTINIQUE, LESSER ANTILLES

Stephen C. AYALA (1) and Paul E. HERTZ (2)

### S U M M A R Y

Plasmodia (Protozoa: Haemosporidiidae) identified as *Plasmodium azurophilum* Telford 1975 were found in 11 of 89 *Anolis roquet* from Martinique in the southern Lesser Antilles. Ten lizards from intermediate elevations had parasites in their erythrocytes, whereas the single infected lizard from a higher elevation rain forest site had parasites only in its leucocytes. Two parasite species could be involved: a garnia-group (pigmentless) plasmodium in the erythrocytes, and a fallisia-group (leucocyte invading) species. If this is the case, then a fallisia-group species is widespread in the Caribbean region as part of the *P. azurophilum* complex. Otherwise, if both stages are part of a single species, the fallisia-group species from other regions in the Neotropics might be expected to show erythrocyte phases at some stage of their life cycle.

### I N T R O D U C T I O N

Some workers on malaria in South and Central American reptiles have preferred to retain all the 39 currently accepted Neotropical parasite species in the single genus *Plasmodium*<sup>1,2</sup>, while others have proposed using several different genera: *Plasmodium* only for pigmented plasmodia using erythrocytes as host cells; *Garnia* for non-pigmented parasites in erythrocytes; and *Fallisia* for plasmodia found in leucocyte host cells<sup>6,7</sup>. The description of *Plasmodium azurophilum* in anole lizards on the Greater Antilles Islands, inhabiting both erythrocytes and leucocytes<sup>9</sup> is an obstacle to those preferring to use the second alternative. Our observation on apparently the same parasite in the Southern Lesser Antilles do not solve the problem, but they help to bring it into clearer focus.

*Plasmodium azurophilum* Telford 1975 and *P. floridense* Thompson & Huff 1944 have been found infecting *Anolis* lizards on several of the

western Caribbean islands<sup>1,2,9</sup> (Table I). We report here the finding of *P. azurophilum* in anoles of a completely different phylogenetic and geographic origin — *Anolis roquet* on the island of Martinique (Figs. 1-3). This finding considerably extends the known distribution of malaria in West Indian reptiles, and raises several questions about its systematics, origin and dispersal.

### MATERIALS AND METHODS

In July 1975, one of us (PEH) collected several series of *A. roquet* as part of a study of its geographical variation and local adaptation<sup>4</sup>. Methanol-fixed blood smears were prepared from lizards from four sites in northern Martinique (Fig. 3): Morne Calebasse (650 meters elevation, elfin rain forest), Petite Savane (500 m, roadside vegetation), Habitation Eden (350 m, banana grove) and Habitation Ajoupa (175 m, banana grove). Animals from the three

(1) Microbiology Dept., Universidad del Valle Medical School; and Tulane University International Center for Medical Research; Apartado Aéreo 5390. Cali, COLOMBIA

(2) Museum of Comparative Zoology, Harvard University, Cambridge. Present address: Dept. of Biological Sciences, Barnard College, Columbia University. New York 10027, U.S.A.

T A B L E I

Known distribution of malaria parasites in *Anolis* lizards of the Caribbean region

Island	<i>Plasmodium floridense</i> <sup>1</sup>	<i>Plasmodium azurophilum</i>
Martinique		<i>A. roquet</i> <sup>2</sup>
Puerto Rico	<i>A. pulchellus</i>	<i>A. krugi</i>
North Bimini	<i>A. sagrei</i>	
Hispaniola	<i>A. cybotes</i>	<i>A. cybotes</i> <sup>2</sup>
	<i>A. distichus</i>	
Jamaica	<i>A. grahami</i>	<i>A. grahami</i>
	<i>A. lineatopus</i>	<i>A. lineatopus</i> <sup>2</sup>
	<i>A. garmani</i>	
	<i>A. opalinus</i>	
Grand Cayman	<i>A. conspersus</i>	
San Andrés	<i>A. concolor</i>	

<sup>1</sup> also known from Central America and the southeastern United States

<sup>2</sup> plasmodia found in leucocytes in some infections

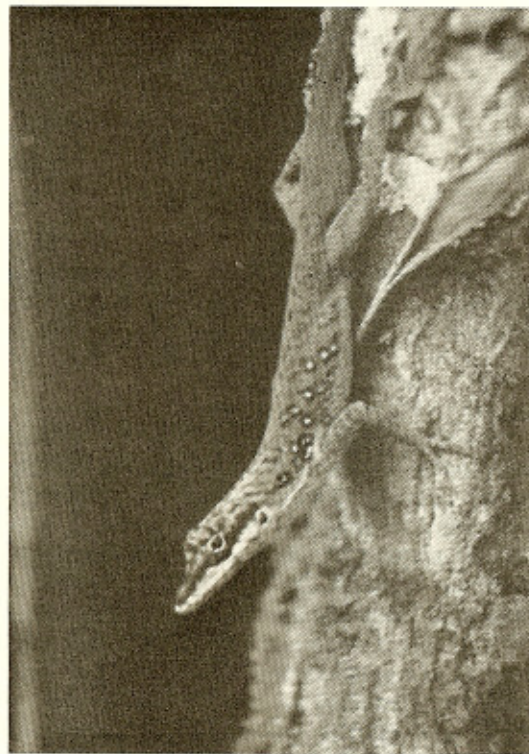

Fig. 1 — *Anolis roquet summus*, a subadult male in survey position on a tree trunk at Petite Savane.

highest sites were assignable to the montane subspecies *Anolis roquet summus*, while those from the 175 m locality were intergrades between *A. r. summus* and the eastern lowland subspecies *A. r. majolgrisi*<sup>5</sup>. The blood smears were stained with Giemsa's blood stain upon arrival in Cali, and examined for hemoparasites at 1000 X magnification.

## RESULTS

We found hemogregarines and plasmodia in the blood smears of lizards from three of the four sites (Table II). Two hemogregarine forms were seen in levels from moderate to scarcely perceptible: an occasional *Schellackia*-like parasite in leucocytes (perhaps *S. golvani* Rogier & Landau 1975, previously known from anoles on Guadeloupe Island), and a *Hepatozoon*-like form (Fig. 13) in erythrocytes. The plasmodia represent either one, or two distinct malaria parasite species.

T A B L E II

Frequency of blood parasite infections in four samples of *Anolis roquet* from northern Martinique Island, July 1975.

Site	Number examined	Hemogregarines	<i>Plasmodium azurophilum</i>
175 m	21	—	—
350 m	23	11 (48%)	6 (26%)
500 m	22	8 (36%)	4 (18%)
650 m	23	—	1 (4%)
	89	19 (21%)	11 (12%)

Lizards from Habitation Eden and Petite Savane harbored plasmodia in developing and mature erythrocytes. Infections were all at a low level, with parasitemias below 1/5,000. Blood pictures were undistorted, with no higher than normal proportion of immature cells suggesting anemia. Infected host cell membranes were weakened, so that they usually appeared rounded, hypertrophied and often they showed small tears on the surface; many apparently ruptured when the slides were made, leaving their parasites free in the blood (Fig. 12). None of the parasites showed any visible pigment. The plasmodia are evidently the same species described by TELFORD<sup>9</sup> as *Plasmodium azurophilum*. Nevertheless, only two infected leu-

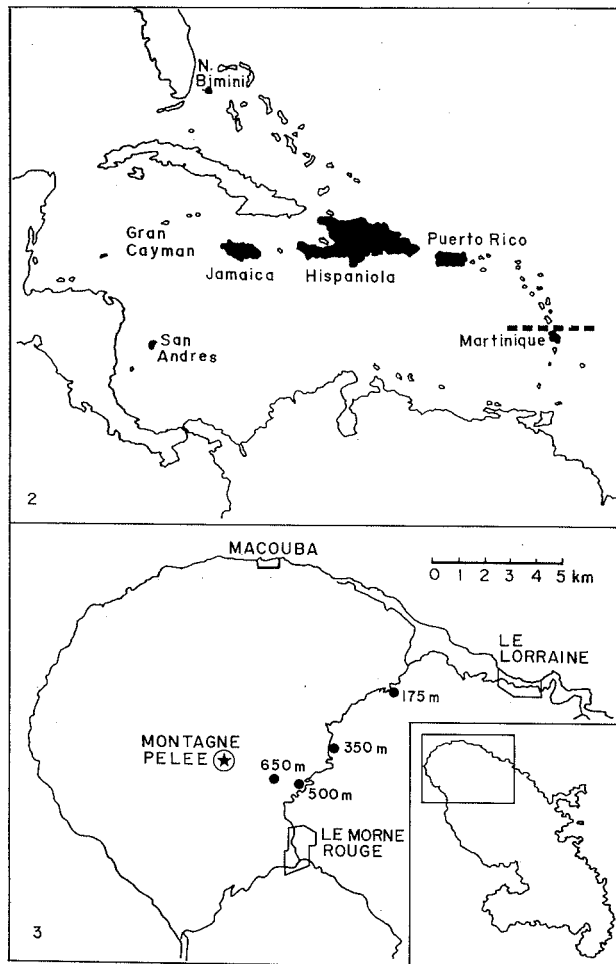


Fig. 2 — *Plasmodium azurophilum*: known distribution of infections in anole lizards of the Caribbean islands (shaded). The dotted line above Martinique indicates the northern limit of the distribution of the roquet species group of South American origin, and the southern limit of the bimaculatus species group of anoles derived from populations on the Greater Antilles. Fig. 3 — Collection sites for *Anolis roquet* on Martinique: Morne Calebasse (650 meters elevation), Petite Savane (500 m), Habitation Eden (350 m), and Habitation Ajoupa (175 m).

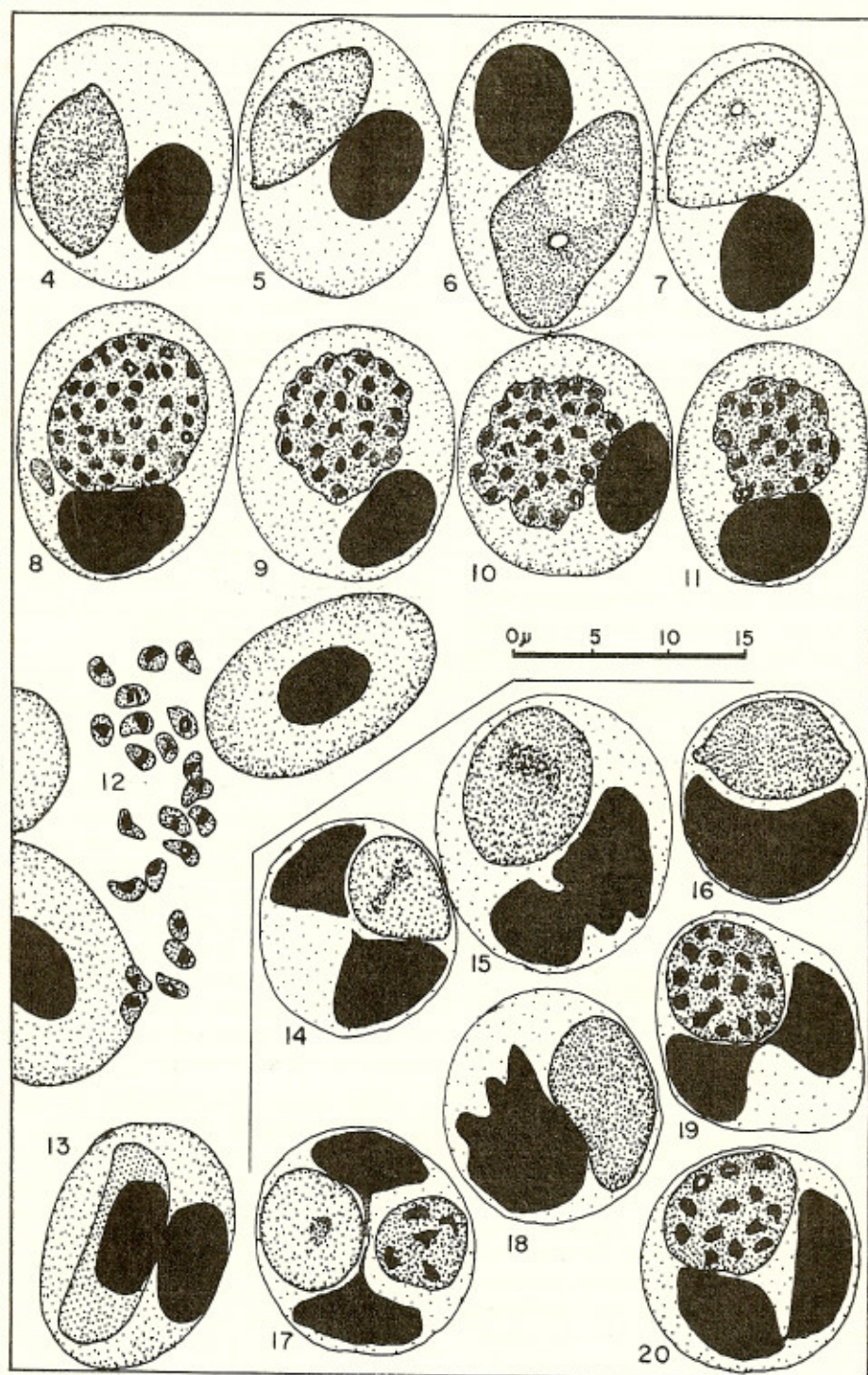
cocytes were found during more than 20 hours of searching the blood smears of 10 different infected lizards.

Plasmodia in the single infected anole from Morne Calebasse inhabited a wide variety of mononuclear and polymorphonuclear leucocytes. The infection apparently stimulated a marked production of these cell types, since they were far more numerous than is normally the case in peripheral blood. Despite a search of more than 10 hours, not a single infected erythrocyte was found, although leucocytes harboring all stages of the parasite were seen about once in every 5 to 10 consecutive 1000 X microscope fields, and multiply-infected leucocytes were common. These parasites appear identical to those described as the leucocyte phase of *P. azurophilum* in anoles of Hispaniola and Jamaica<sup>9</sup>. They are also very similar to *Fallisia* (=Plas-

*modium*) *modestum* and to other leucocyte-inhabiting plasmodia on the South American mainland<sup>6,7</sup>.

## DISCUSSION

The malarial parasite from Greater Antilles anoles named *Plasmodium azurophilum* by TELFORD<sup>9</sup> thus also infects anoles on Martinique. The picture is complicated by the virtually complete separation of erythrocyte and leucocyte forms in different lizards, although Telford noted this same situation for the other anole hosts. In fact, were it not for Telford's thorough description, our plasmodia would unhesitatingly have been identified as two distinct species: a pigmentless (garnia group) species inhabiting erythrocytes, and a leucocyte-inhabiting (fallisia group) species similar to those known from several Brazilian lizards<sup>6,7</sup>.



Figs. 4-20 — Hemoparasites from *Anolis roquet*: 3-11 malarial gametocytes, schizonts and merozoites in erythrocytes of lizards from Petite Savane; 12, typical large hemogregarine in erythrocyte; 13-20 malarial gametocytes and schizonts in various leucocyte types in lizard from Morne Calebasse.

Additional material must be studied to test Telford's belief that *P. azurophilum* is not actually a composite species. If it turns out that two distinct parasites are involved, then a fallisia group species similar to those known from northeastern Brazil is widespread in the Caribbean region.

A careful reading of the *P. azurophilum* description suggests that two distinct species could be involved. The total number of naturally infected lizards with plasmodia in their leucocytes was small: three *A. lineatopus* from Jamaica and five *A. cybotes* from Haiti (Table I). None were found in the single infections in *A. grahami* and *A. krugi*. In addition, they were found in two experimentally infected *A. cybotes*: the host cell type(s) in the first donor was not stated, but in the second case there were no plasmodia found in the erythrocytes of the donor host, and only leucocyte stages developed in the recipient.

In on the other hand, *P. azurophilum* does prove to be a single species capable of infecting both white and red blood cells at different, as yet undescribed phases of its life cycle, then we should probably look for similar "erythrocyte phases" at some stage of the infection cycle of the other fallisia group species.

A remarkable proliferation of host leucocytes as a consequence of plasmodial infection has been seen on other occasions with leucocyte-invading parasites. TELFORD<sup>9</sup> noted it in one of his two experimentally infected *A. cybotes*, and we (Ayala & Guerrero, unpublished) saw a similar reaction in an *A. frenatus* from central Panama carrying an undescribed plasmodia in its leucocytes. Whatever the mechanism, the result is a striking increase in the appropriate host cells.

*Anolis roquet* is a widespread ecological generalist, the only anole on the island of Martinique. It has differentiated into six recognizable subspecies which tend to occupy different climatic habitats on the island<sup>5</sup>. HERTZ<sup>4</sup> identified physiological differences between the different subspecies. *Anolis roquet summus*, the form in which we found the infections, occurs continuously throughout the mountains of northern Martinique in dense rain forest and in disturbed habitats.

*Plasmodium azurophilum*, like *P. floridense*, infects anoles of quite different genetic and

geographic origins<sup>2,11,12</sup>. It occurs in anoles of both the South American-derived alpha lineage (*A. roquet*, *A. cybotes*, *A. krugi*), and the Meso American-derived beta lineage (*A. grahami*, *A. lineatopus*). Perhaps it can infect almost any anole population living in regions suitable for the insect vector species.

Infected lizards surely carry their parasites with them when they colonize new islands. The *bimaculatus* species group of anoles living on the northern Lesser Antilles (St. Croix south through Dominica) are in fact derived from stocks on Puerto Rico in the Greater Antilles<sup>5</sup>, where *P. azurophilum* is known to occur. However, *A. roquet* and all the other anole species on the islands south of Martinique are derived from a different stock of colonists from the adjacent South American mainland<sup>3</sup>. Thus, the presence of *P. azurophilum* on Martinique can not be explained by a simple southward dispersal of infected lizards from the Greater Antilles, unless it was brought in and established *bimaculatus* group lizards whose own effort at colonization later failed<sup>11</sup>.

If *P. azurophilum* is truly a unique species of Caribbean origin, it may be that a representative of the *bimaculatus* species group did once inhabit Martinique, from which it was later displaced by *A. roquet*, while leaving behind a malarial infection as a reminder of the period of encounter. Nevertheless, two other factors need also be considered: 1) the probable ease with which flies (including malaria-infected Diptera) might be wind-dispersed between islands, and 2) the effect on animal dispersal of the much increased size of the island banks (and hence, reduced distance between islands) as recently as 15,000 years ago during the Pleistocene sea level lowerings.

Two other circumstances suggest further study of *A. roquet* and its infections on Martinique would be worthwhile. If Phlebotomine sandflies are involved as insect vectors<sup>1</sup>, the situation could be convenient to study, since these insects are not generally abundant on the Caribbean islands — only a single species having been reported so far from Martinique, and it apparently feeds on reptiles (WILLIAMS & COELHO<sup>13</sup>, and other reports cited therein). Finally, *Anolis roquet* on Martinique is also the only reported lizard host of *Leishmania* ("*Leishmania henrici*") in New World reptiles<sup>8</sup>. This report has never been followed up, although it

now seems likely that these parasites, assuming that they were really Trypanosomatids, were probably monoxenous flagellates from ingested insects rather than true Leishmania.

## RESUMEN

### Infección malarica en saurios del genero *Anolis* en la isla Martinique, Antillas menores.

En 11 de 89 *Anolis roquet* de la isla antillana de Martinique, fueron encontrados parásitos malaricos identificados como *Plasmodium azurophilum* Telford 1975. Diez lagartos capturados a 350 y 500 metros de elevación presentaron plasmodios en sus glóbulos rojos, mientras el único animal positivo encontrado a 650 metros en selva montano pluvial tenía parásitos abundantes pero exclusivamente en los leucocitos. Es posible que se trate de dos especies distintas de plasmodios: una que infecta eritrocitos sin producir pigmento malarico (del grupo "garnia"), y la otra que reside en leucocitos (del grupo "fallisia"). En este caso, un plasmodio representante del grupo fallisia se encuentra ampliamente distribuido en islas del Caribe, conocido hasta ahora como "la fase leucocitaria" de *P. azurophilum*. Si por el contrario las dos formas son realmente fases de una sola especie que infecta ambos tipos de células, entonces debemos buscar en las otras especies del grupo fallisia para averiguar si ellas tambien presentan formas eritrocíticas en alguna fase de su ciclo normal.

## ACKNOWLEDGEMENTS

We thank P.G. Haneline, A.S. Rand and Fanny Carvajal for preparing, requesting and transporting, and preliminary study of the blood slides. The work was made possible by grants from the National Science Foundation (GB 37731X to Dr. Ernest E. Williams and DEB 75-16334 to P.E. Hertz), the Richmond and Anderson Funds of Harvard University and the Explorer's Club of New York (to P.E. Hertz), and the U.S. Public Health Service (NIH AI-12511 to S.C. Ayala).

## REFERENCES

1. AYALA, S. C. — Plasmodia of Reptiles. In *Parasitic Protozoa*. J. P. Kreier, ed. New York, Academic Press, 3: 287-309, 1977.
2. AYALA, S. C. — Checklist, host index, and annotated bibliography of *Plasmodium* in reptiles. *J. Protozool.* 25: 87-100, 1978.
3. GORMAN, G. & ATKINS, L. — The zoogeography of Lesser Antillian *Anolis* lizards — an analysis based upon chromosomes and lactic dehydrogenases. *Bull. Museum Comparative Zool. (Harvard University)* 138: 53-80, 1969.
4. HERTZ, P. E. — Altitudinal variation in thermoregulatory strategies, physiological ecology, and morphology of some West Indian anoles. [Doctoral dissertation], Harvard University, 1977, 280 pp.
5. LAINSON, R.; LANDAU, I. & SHAW, J. J. — Further parasites of the family Garniidae. Coccidiida: Haemosporididae) in Brazilian lizards. *Fallisia effusa* gen. nov., sp. nov., and *Fallisia modesta* gen. nov., sp. nov. *Parasitology* 68: 117-125, 1974.
6. LAINSON, R.; SHAW, J. J. & LANDAU, I. — Some blood parasites of the Brazilian lizards *Plica umbra* and *Unranoscodon superciliosa*. *Parasitology* 70: 119-141, 1976.
7. LAZELL, A. — The anoles (Sauria: Iguanidae) of the Lesser Antilles. *Bull. Museum Comparative Zool. (Harvard University)* 143: 1-115, 1972.
8. LEGER, M. — Infection sanguine par *Leptomonas* chez un saurien. *C. R. Séanc. Soc. Biol. (Paris)* 81: 772-774, 1918.
9. TELFORD, S. R. — Saurian malaria in the Caribbean; *Plasmodium azurophilum*, sp. nov., a malarial parasite with schizogony and gametogony in both red and white blood cells. *Int. J. Parasitol.* 5: 383-394, 1975.
10. ROGIER, E. & LANDAU, I. — Description de *Schellackia golvani*, n. sp (Lankesterellidae), parasite de lézards de Guadeloupe. *Bull. Museum Natl. Hist. Nat. (Paris) (Zoologie)* 194: 91-97, 1975.
11. WILLIAMS, E. E. — The ecology of colonization as seen in the zoogeography of anoline lizards on small islands. *Quart. Rev. Biol.* 44: 345-389, 1969.
12. WILLIAMS, E. E. — West Indian anoles: a taxonomic and evolutionary summary. I — Introduction and species list. *Breviora, Museum Comparative Zool. (Harvard University)* 440: 1-21, 1976.
13. WILLIAMS, P. & COELHO, M. de V. — Taxonomy and transmission of *Leishmania*. *Adv. Parasitol.* 16: 1-42, 1979.

Recebido para publicação em 29/4/1980.